

# Neurocritical Care Unit Case Study:

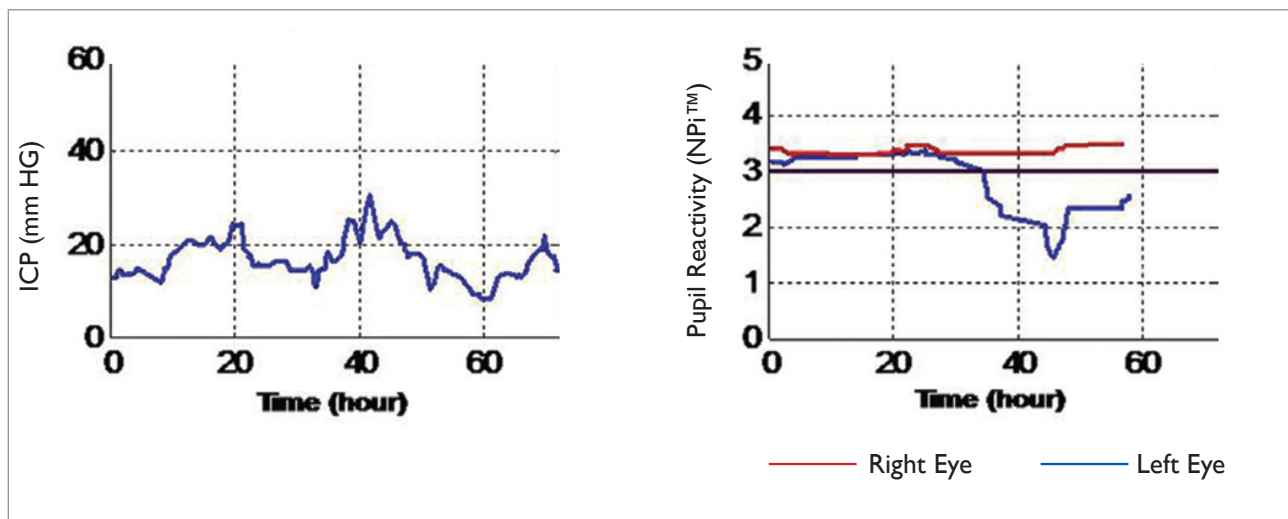
## Pupillometer Use in Traumatic Brain Injury (TBI)

### CLINICAL BACKGROUND

The patient presented with a traumatic brain injury (TBI) with subdural hemorrhage distributed over the left frontal, temporal and parietal lobes. The pre-enrollment CT scan revealed a left to right midline shift of 18 mm, and a mass size of 25 cm<sup>3</sup> on the left lobe that later enlarged to 30 cm<sup>3</sup>. Cisterns were absent or compressed. Pupillometry reading resulted in normal Neurological Pupil index (NPI™) readings initially.

### CLINICAL NOTES

Intracranial Pressure (ICP) values were initially maintained below 20 mm Hg using medical interventions and cerebral spinal fluid (CSF) diversion, but then increased above 20 mm Hg at around hour 20. ICP decreased again and it finally peaked at over 30 mm Hg at around hour 40. Another CT scan revealed a left to right midline shift of 11 mm and a pronounced effacement of the basal cisterns, which suggested impending herniation. Extensive edema was also seen throughout the left cerebral hemisphere. A few hours before this CT scan and the second elevated peak of ICP, the left pupil NPI™ reactivity decreased below the normal threshold and it remained abnormal for the rest of the study.



### DISCUSSION

Evaluation of pupil size and its light reflex mechanism is an integral part of the protocol of the treatment and management of severely brain injured patients. Both the American Association of Neurological Surgeons and the Brain Trauma Foundation guidelines recommend that severe TBI patients be evaluated for asymmetry in pupil size and pupil reactivity to light, as well as fixed and/or dilated pupils.

The TBI literature provides evidence that alterations of the pupil light reflex, pupil size or pupil equality are all closely correlated with clinical outcome. Dilation of a pupil and subsequent herniation are late events

and frequently irreversible. A more sensitive means to track pupillary changes, in order to detect potential ICP problems before a monitor is inserted, would be of particular utility for the triaging of patients.

## SUMMARY

The NPI™ may provide a non-invasive means to track and predict problems with ICP, providing beneficial guidance for neurological therapy to improve patient outcomes.

## REFERENCES

1. Chen JW, Gombart ZJ, Rogers S, Gardiner SK, Cecil S, Bullock RM. Pupillary reactivity as an early indicator of increased intracranial pressure: The introduction of the Neurological Pupil index. *Surgical Neurology International* 2011;2:82.
2. Guidelines for the Management of Severe Traumatic Brain Injury, 3rd edition, Brain Trauma Foundation. 2007.

© 2014 NeurOptics, Inc. All rights reserved.

Australia & NZ

p: (+61) 1300 433 905

m: 0430330767

f: (+61) 1300 367 266

e: sales@jrmedicalsupplies.com.au

www.jrmedicalsupplies.com.au

NEUR<sup>••</sup>OPTICS

 **JR** MEDICAL SUPPLIES

Case Study - NICU - No. 2  
April 2014